

3

6 25 15
 ASHMISSON SHERRI
 00 2 24 85
 59A
 LAPD VV

Informant: Pida #11981 L.A.P.D. Van Nuys Division. Other personnel present were Det. Mayer #11272/Hook #22175, Giles #09539 Photo, Aguilar #A8715 Prints and Criminalist CME Maharmey.

Synopsis: The decedent was found in her residence with gunshot wounds and was declared at the scene.

Investigation: This case was reported to the coroner's office by Hooks, 2300 hrs. 2/24/86. L.A.P.D. Van Nuys Division.

The decedent shares a residence with her husband John Ruetton at 7100 Balboa Blvd. #205, Van Nuys. The decedent was last known to be alive at 0720 hrs. 2/24/86 when the husband left the residence. He returned to the residence at 1755 hrs. to find the decedent and summon medical assistance. The police received an alarm at 1759 hrs. Paramedic Goldsworthy, L.A.F.D. RA #93, indicated the the L.A.P.D. unit on the scene was 9A49. Ra #93, Carr/Telian, were dispatched at 1800 hrs. and arrived on the scene at 1808 hrs. The decedent had face trauma and was in rigor. The decedent was declared at 1812 hrs.

Upon arrival of the coroner's investigator, 0055 hrs., the decedent was observed lying in a semi supine position on the carpeted livingroom floor. Examination of the 29 year old female Caucasion revealed her to be dressed in panties, T-shirt and robe.

The decedent had numerous points of trauma. The decedent had three bullet type wounds to the chest. One of the wounds appeared to be a contact wound with fragments of the robe imbedded in the wound. There were holes noted in the robe with speckling. There were two exit type wounds in the decedents back. One of the wounds had a bullet protruding while the other wound was clear. A bullet may be lodged in the clothing that was not located at the scene. A distended area was noted on the back that may be a bullet under the skin. Another bullet type wound was noted under the decedents right eye with no indication of an exit wound. A laceration was also noted in the right eyebrow. At the coroners office several more lacerations were noted around the eye. Also noted at the coroners office were two circular abrasions around the right eye. An abrasion was noted on the left side of the decedents throat and another on the left cheek. Sooting was noted on the right index finger. The septum of the upper lip was noted to be torn and bruised. A bite mark was noted on the decedent left forearm on the anterior surface.

Dr. Veil was notified of the bite mark at 0600 hrs. 2/25/86 and responded to the coroner's office for investigation at 0800 hrs. All other evidence collected by Criminalist Maharmey.

ID: was made to the police by the husband per Det. Pida.

Please call Pida/Mayer/Hooks one hour prior to post time, (818) 989-8383

900
 Sgt Meter will not sign
 [Signature]

[Signature]
 Walter R. Rainey
 2/25/86.

INVESTIGATOR

DATE

WHITE - FILE
 YELLOW - TOXICOLOGY
 PINK - INVESTIGATIONS

6

ENVIRONMENT TEMPERATURE INFORMATION

DATE 2/25/86
AIR 65 °F TIME 0125
WATER _____ °F TIME _____

85 267h
RASMUSSEN SHERRI
DOB 2 24 85
H 59A
LAPD VN

LIVER TEMPERATURE 85 °F DATE 2/25/86 TIME 0240

TAKEN AT SCENE

DATE & TIME FOUND 2/24/86 1812 LAST KNOWN ALIVE 0730 2/24/86

AGE 29 SEX F HEIGHT 72 WEIGHT 150 CLOTHED? YES NO IF YES-DESCRIBE:

PANTIES TROUSERS T-SHIRT

DESCRIPTION AS TO WHERE REMAINS FOUND AND CONTACT MATERIAL TO BODY:

CARPETED LIVINGROOM FLOOR

SCENE TEMPERATURE REGULATED? YES NO IF YES THERMOSTAT SET AT _____ DEGREES F.

LIVOR MORTIS: +1 BLANCHES

RIGOR MORTIS

NECK FLEXION: 4

ANTERIOR _____

POSTERIOR _____

RT. LATERAL _____

LT. LATERAL _____

JAW 4 _____

HIP _____

SHOULDER _____

KNEE _____

ELBOW _____

ANKLE _____

WRIST _____

SCALE

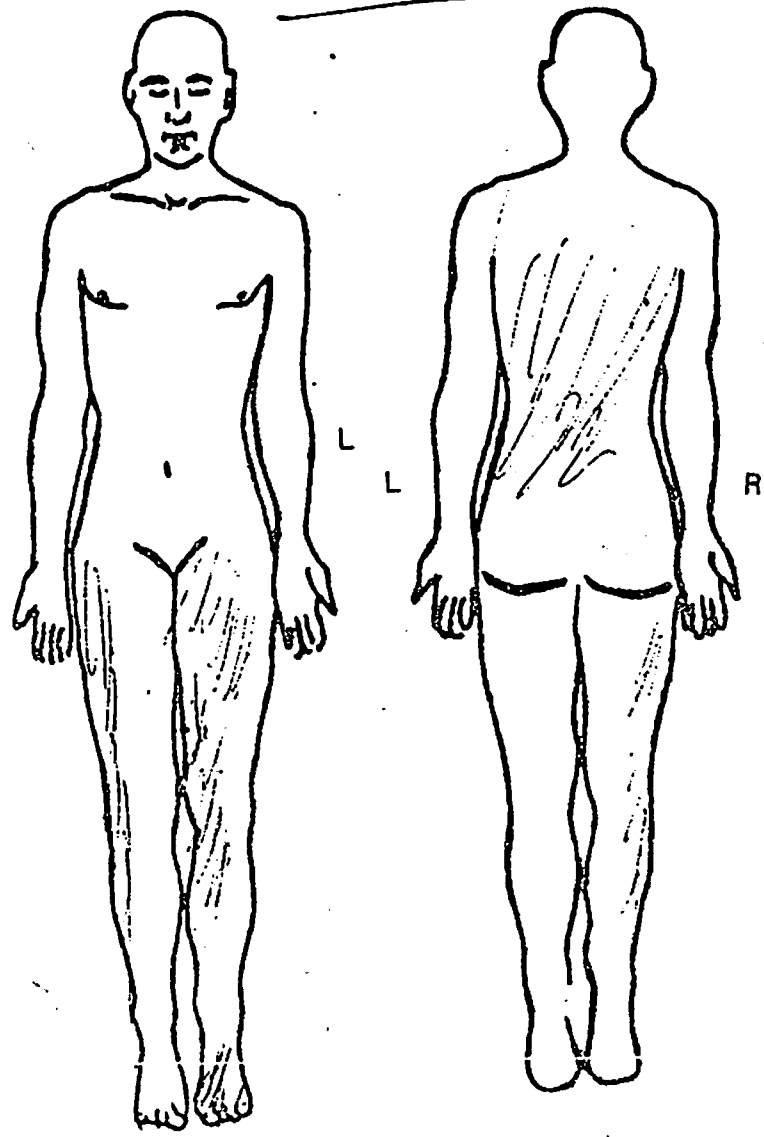
- 0 = ABSENT/NEGATIVE
- 1 +
- 2 +
- 3 +
- 4 = EXTREME DEGREE

USE SCALE TO DESCRIBE INTENSITY OF LIVOR MORTIS AND RIGOR MORTIS.

SHADE DIAGRAMS TO ILLUSTRATE THE LOCATION OF LIVOR MORTIS.

DESCRIBE INTENSITY OF COLORATION AND WHETHER LIVOR MORTIS IS PERMANENT OR BLANCHES UNDER PRESSURE.

Walter R. Ramsey
Coroner's Investigator



12**AUTOPSY REPORT**

No.

86-2676

RASMUSSEN, SHERRI

Page 2**DESCRIPTION OF GUNSHOT WOUNDS:**

The gunshot wounds are arbitrarily labelled for the convenience of the examiner and do not necessarily indicate a sequence of injury.

GUNSHOT WOUND #1:

Entry: To the mid chest 17 inches from the top of the head is a 1/4 inch defect surrounded by an area of distinct abrasion extending up to 2/16 of an inch. There is blistering noted along the skin of the upper part of the wound extending up to approximately 1/4 of an inch. Blackish soot is noted along the wound defect and wound track. No stippling is noted.

Exit: Located along the posterior right back 18 inches from the top of the head and 3 inches to the right of the midline is a 1/2 x 1/4 inch irregular defect showing abraded edges extending up to 1/8 of an inch consistent with a short exit effect. No soot or stippling is seen on the skin surface at the time of the autopsy.

Path: The hemorrhagic wound track passed through the skin and subcutaneous tissues of the center chest and entered the chest cavity passing at the 3rd intercostal space just immediately to the right of the sternum. There is cherry-red discoloration of the musculature underlying the entry wound. A slight amount of blackish soot is noted. The wound entered the rib cage slightly grazing the undersurface of the second rib. The wound track then passed through the hilus of the right lung damaging the right main bronchus and parenchyma of the right lung to exit the pleural cavity at the posterior 6th rib slightly grazing the undersurface of the rib.

12

AUTOPSY REPORT

No.
86-2676
RASMUSSEN, SHERRI

Page 3

Trajectory: Front to back, slightly left to right and slightly downward.

Missile: See below.

GUNSHOT WOUND #2:

Entry: Just above the left breast 16 inches from the top of the head and 3-1/2 inches to the left of the midline along the anterior left chest wall is a 1/4 inch defect surrounded by a 1/16 inch area of abrasion. No obvious soot or stippling is seen on the skin surface at the time of the autopsy.

Exit: No exit.

Path: The hemorrhagic wound track passed through the skin and subcutaneous tissue and entered the chest cavity at the 3rd intercostal space on the left without fracturing the upper or lower ribs. There is no discoloration of the underlying musculature or soot seen along the wound track. The wound track then passed along the mediastinal tissues and lacerated through the descending thoracic aorta with a 3/4 inch stellate defect and penetrated into the body of the thoracic vertebrae at the level of T4-5 to lacerate through and through the spinal cord. The missile then became embedded in the subcutaneous tissues of the back from which site it is recovered at autopsy.

Trajectory: Front to back, left to right and slightly downward.

Missile: Recovered at autopsy from the subcutaneous tissues of the back at 11:10 A.M. on this date is a 9 mm. silvery flattened-nose, gold based missile recovered from the subcutaneous tissues of the mid back. It is not marked across the base, shows minimal deformity and it is placed in a labelled evidence envelope and kept in my pocket until it is dropped in the Evidence Box at approximately 2:00 P.M. on this date.

12

AUTOPSY REPORT

No.

86-2676

RASMUSSEN, SHERRI

Page

4

GUNSHOT WOUND #3:

Entry: To the lower left chest 21 inches from the top of the head and 2 inches to the left of the midline is a 1/4 inch defect surrounded by a 1 to 2/16 of an inch distinct area of abrasion. There is no obvious soot or stippling seen on the skin surface at the time of the autopsy.

Exit: Located along the lower left back 21 inches from the top of the head and 1-1/2 inches to the left of the midline is a 1/4 inch defect showing some slight tearing of the edges and possible slight abrasion. No soot or stippling is noted in the skin surface at the time of the autopsy.

Path: The hemorrhagic wound track passed through the skin and subcutaneous tissues as noted and entered the chest cavity at the 6th intercostal space slightly grazing the edges of the 6th rib. There is some slight reddish discoloration of the underlying musculature, minimal, and no soot is noted. The bullet then passed through the pericardial sac with 1/4 inch defects and through the heart entering the right ventricle with a 3/4 inch hemorrhagic defect, septum of the heart with a large 2 inch defect and exited the posterior left ventricle with a 1 inch defect to then pass through the left lower lobe of the lung with a 1/2 inch hemorrhagic defect. The missile then exited the body at the posterior 7th intercostal space and exited the posterior lower left chest wall as noted.

Trajectory: Front to back, slightly upward and slightly left to right.

Missile: See below under Note.

Note: A missile is received from the photographer, Carlos Salia by myself at approximately 9:30 A.M. The photographer reports that the missile dropped from the posterior aspect of the body upon removal of the clothing. It therefore is consistent with the missile from Gunshot Wound #1 or #3.

12

AUTOPSY REPORT

No.

86-2676

RASMUSSON, SHERRI

Page 5

The missile is placed in a labelled evidence envelope and kept in my pocket until it is dropped in the Evidence Box at approximately 2:00 P.M. on this date.

OTHER INJURIES:

1. Above and along the medial aspect of the right eyebrow is a 1/2 inch area of laceration.
2. Along the lateral mid right forehead is a 1/4 inch slightly curved reddish-purple abrasion.
3. Just below the lateral right eyebrow is a 1/4 inch slightly curved abrasion.
4. Along the tissues of the upper eyelid is an area of 1/2 inch laceration, slightly lateral to it a 1/4 inch curved near circular abrasion and lateral to it a 1/2 inch area of abrasion laceration.
5. Along the tissues just to the lateral aspect of the right eye are two (2) 1/4 inch areas of laceration with generalized abrasion.
6. Along the upper mid right cheek is a 1/4 inch laceration with a 3/4 inch area of abrasion.
7. Along the right cheek are 2 superficial yellowish-tan 1/16 inch areas of abrasion and a 1/4 inch area of superficial yellowish-tan abrasion or possible cutting wound.
8. Lateral to the right side of the mouth are two (2) 1/4 inch superficial areas of apparent scratch abrasion.
9. Along the chin on the right side is a 1/4 inch abrasion, below it a 1/4 inch abrasion and along the lower left side of the chin a 1/4 inch abrasion.

12

AUTOPSY REPORT

No.

86-2676

RASMUSSEN, SHERRI

Page 6

10. There are small faint fine petechiae noted in the conjunctiva of the left eye. There is diffuse petechial hemorrhage and contusion ecchymosis along the tissues of the right eye. There is generalized contusion ecchymosis along the tissues of the right eyelid. There is also some fine punctate petechiae noted on the skin of the neck and upper chest.
11. The right ear shows a generalized area 2 inches of reddish-purple contusion.
12. Just anterior to the right ear is a 1 inch zone of reddish-purple contusion.
13. The left side of the head shows above the left ear canal a generalized 3 inch area of contusion containing a 1/4 inch area of abrasion, a 1/2 inch area of laceration and a 1/2 inch area of abrasion contusion.
14. Along the lateral left cheek is a 3/4 inch area of scratch abrasion, a 1/4 inch area of yellowish-tan slightly hemorrhagic purple abrasion; and a 1/4 inch area of scratch abrasion.
15. Just beneath the left side of the chin is a 1/2 inch area of yellowish-tan slightly purple abrasion.
16. Along the anterior right chest is a 1/8 inch area of superficial abrasion.
17. Along the anterior pubic symphysis is a very superficial slight 1/4 inch area of abrasion.
18. The upper extremities show at the inner left elbow a generalized 3 inch zone of contusion containing a 1-1/2 inch area of scratch abrasion contusion and two (2) 1/2 and 1/4 inch areas of scratch abrasion contusion.

20

GSW #1 Ent chest
17" toh

dy 1/4" sun
chess part merged
up to 7/16"
super binding 'b
sl up to 1/4"
blackish sooty
along wound

31L space
just R of sternum
cherry red
muscle disc
elw CO effect
at soot
sl graze
2 ribs

GSW #1
Exit B

Path
- R. L. of 9th
K lung
amp blood
w/le

Tray
F > B
sl L > R
sl down

muscle none nec
none
muscle nec at neck
muscle nec 11" am
9mm silver steel
nose gold base
nec subcut tissue
mid back
not nec
- dy
ass to GSW
#2

GSW #2 16" toh
Ent find above L breast
3 1/2 Lcm
dy 1/4" sun abn ~ 1/16"
no obs soot on
stip seen to shi surface
31L up L no fr
no CO effect at soot

NO exit
muscle recover
at autopsy

Path
muscle none yes
spine spine

Tray
F > B
L > R
sl down

Muscle

Exit A GSW #3
17 1/2 toh
2 1/2 Lcm
1 1/2 Lcm
dy
1/4 in dy
tan edges
sl abn
p/w soot
no soot on tip
no ill dx
past

Ent GSW #3
lower left side
21" toh
2" Lcm
dy 1/4"
seen abn dx
1/16 - 7/16"
no obs soot
slip on shi
surface

6 Lcm
sl
edge
muscle
disc

Path
Exit #3
Exit

Path
Flank
L-L

Tray
F > B
sl up
sl L > R

GSW #1 Exit A
Exit B
18" toh
3" ROM
1/2 x 1/4 in
dy abn
1/8 edges
no soot on tip
Ch should not
fr nec on tip

GSW
2 site
muscle
nec

GSW
at Exit
Exit
GSW
(shard)

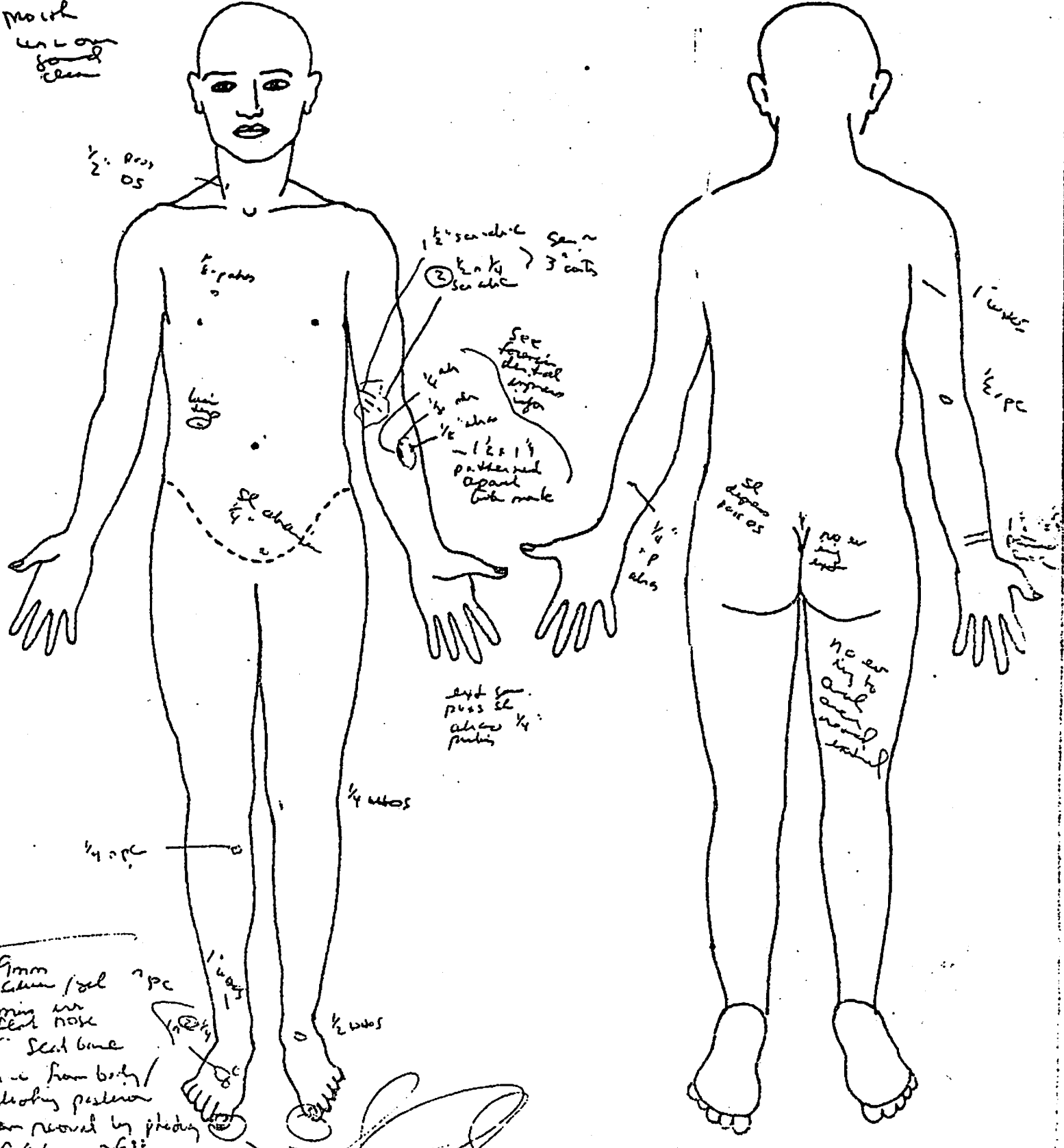
A
Exit
GSW #3
p/w shard

[Signature]

20

WOWCF, cool, mental and, hair nigr, pct hie
Hair brown 3-4"
Eyes green P 2 - L 5.00 clear pale fair pct hie
R 5.00 clear cig small eye
canon den

Nose ee blandy skind, no poly fix nose a face bones
Ears dray no skind at ant
Mouth
ear on
found
clean



1/2 inch scar
OS

1 1/2 inch scar
2 inch scar
3 cuts

1/2 inch scar
1/2 inch scar
1 1/2 inch scar
padded
apart
with mark

1/2 inch scar
OS

1 inch scar

1/2 inch scar

1/2 inch scar
puss
above 1/4
punch

1/4 inch scar

1/4 inch scar

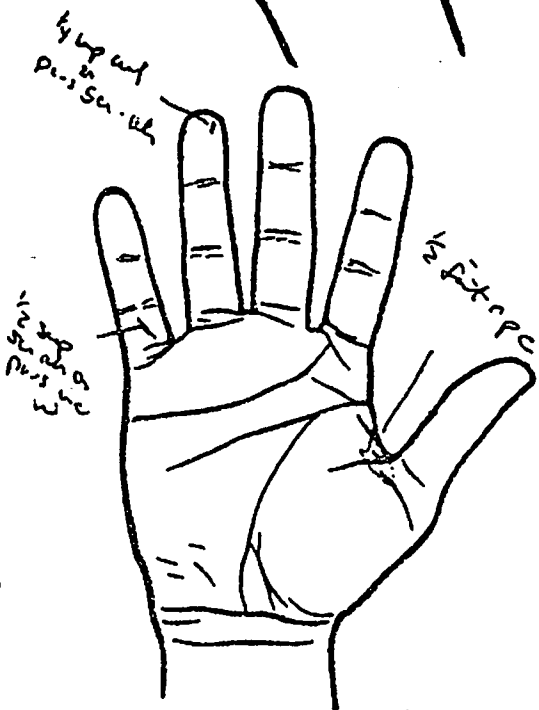
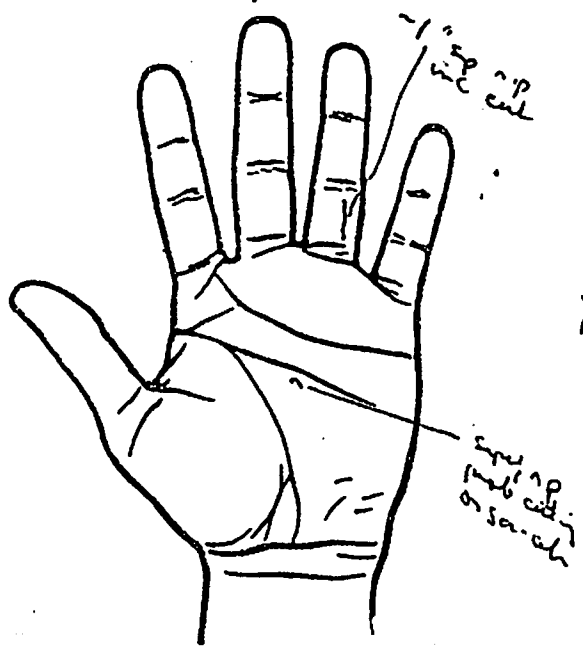
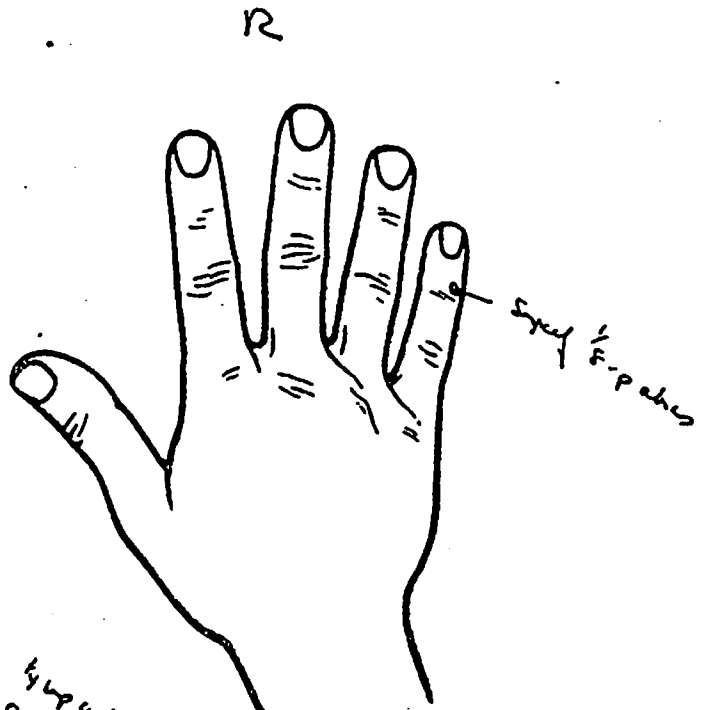
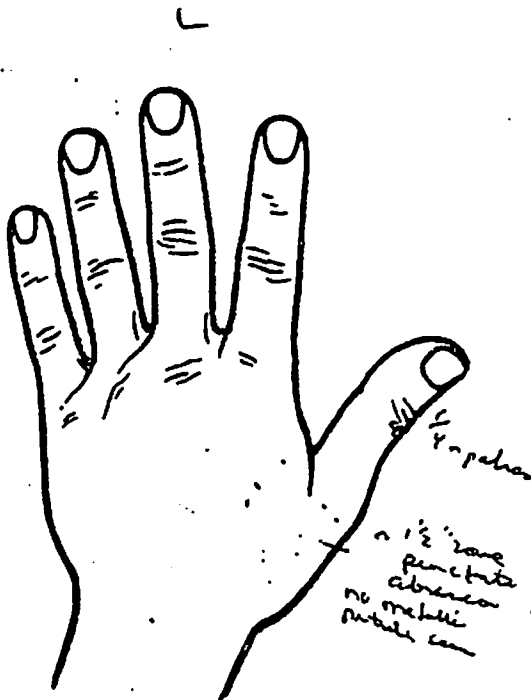9mm
clean / sel 7pc
min in
left nose
Seat bone
inc from body/
clothing posterior
an record by photo
C. Celaya 4/92
Shars

[Handwritten signature]

M.D. Deputy Medical Examiner

20 E

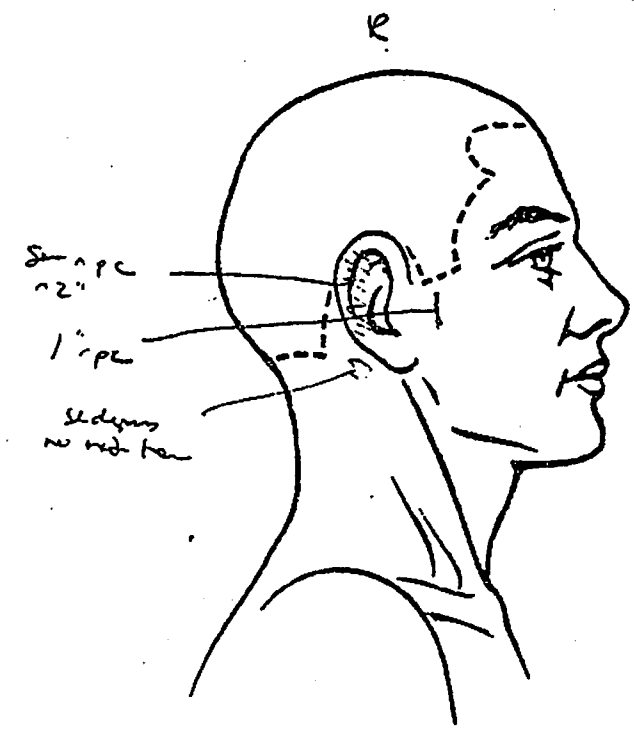
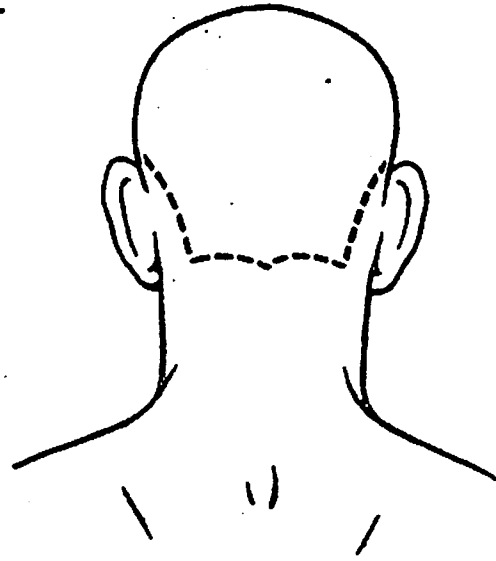
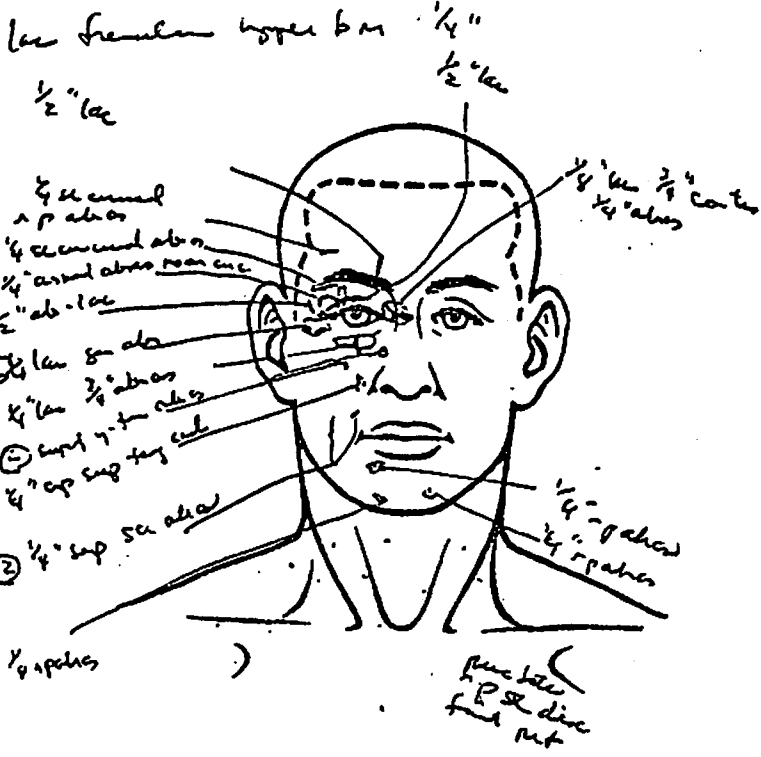

15 15 15 15 15
100 100 100 100 100



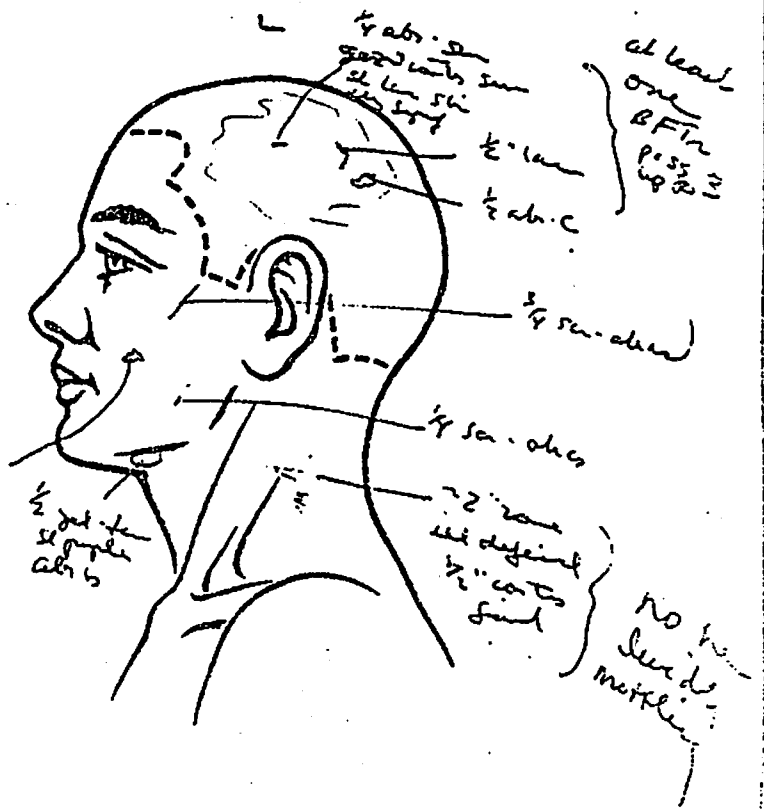
Deputy Medical Examiner.

20 F

Gen cracc super Rescaled



side of
right
left
etc



[Signature]
Deputy Medical Examiner.